

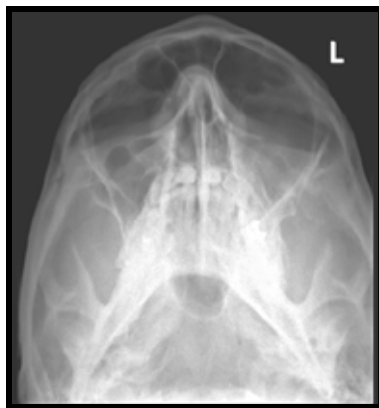## PLAIN FILMS IN THE HEAD & NECK

Increasingly cross sectional imaging has replaced plain film in the head and neck, but plain film still has a role for a group of specific indications.

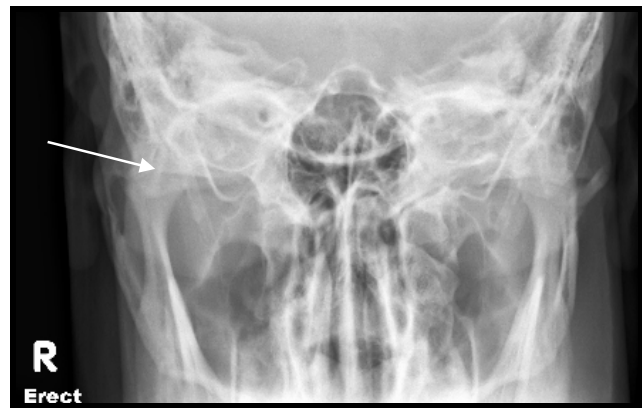
### FACIAL TRAUMA

Plain films of the skull are of limited value in the context of trauma. A large proportion of patients with intracranial injury may have no fracture at all and some important fractures can be difficult to diagnose on XR, such as fractures of the petrous temporal bones.

In mid face injury, facial views can detect fractures of sinus walls and can be used to triage those requiring CT. These images demonstrate a step in the left orbital floor and a right zygoma fracture.

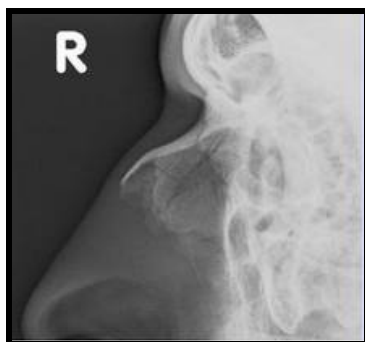

**FRACTURE LEFT ORBIT  
FLOOR**

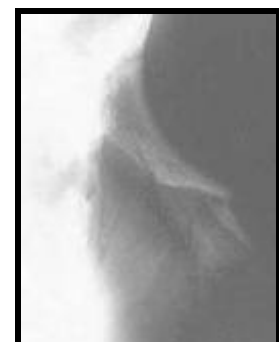
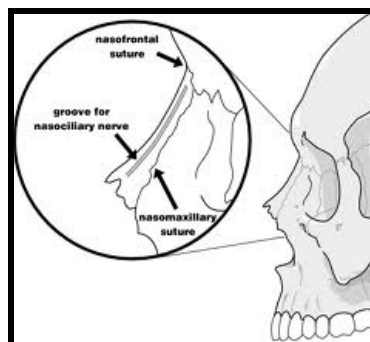


**FRACTURE RIGHT ZYGOMA**

The diagnosis of nasal fracture is clinical and imaging is often unnecessary and potentially confusing. Normal sutures and grooves can mimic fractures and, even when positive they do not usually affect patient management.



**NORMAL NASAL BONES**

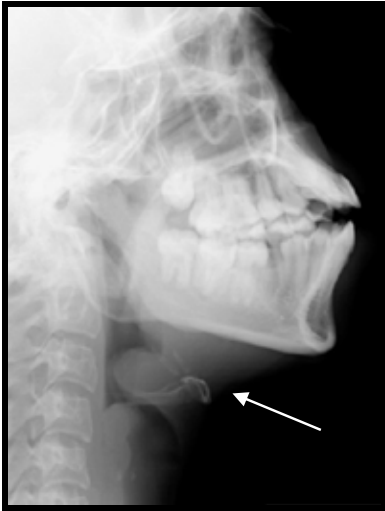

**FRACTURED NASAL  
BONE**

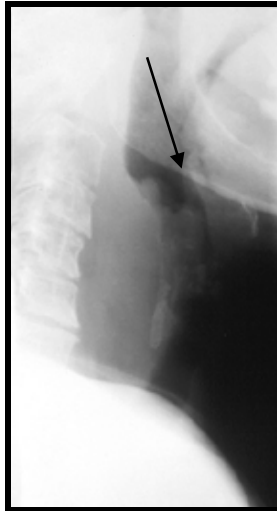
### SINUSES, LATERAL SOFT TISSUE NECK AND ADENOIDS

There is no role for plain XR in the assessment of inflammatory sinus disease. Lateral soft tissue neck radiographs can be useful in suspected epiglottitis or retropharyngeal abscess. Lateral views of the nasopharynx in children can be helpful to look for adenoid hypertrophy in the context of chronic cough, recurrent otitis media, nasal blockage or snoring.

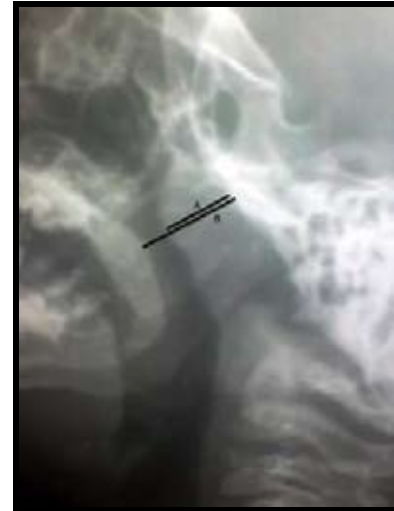Grading adenoid hypertrophy is based on how much of the nasopharyngeal airway is blocked: Grade 1 <25%, Grade 2 25-50%, Grade 3 50-75% and Grade 4 >75%. This is determined by measuring the thickness of the tissue from the pharyngeal tubercle of the clivus to the maximum convexity of the adenoid (A) divided by the distance from the same point on the clivus to the nasopharyngeal surface of the soft palate (B).



**EPIGLOTTITIS**



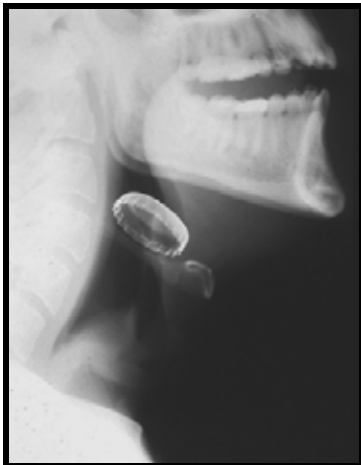**RETROPHARYNGEAL  
ABSCESS**



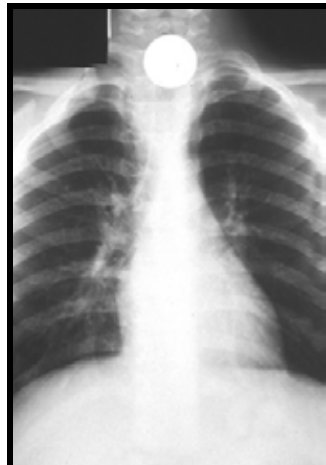**GRADE 3  
ADENOIDHYPERTROPHY**

### FOREIGN BODY

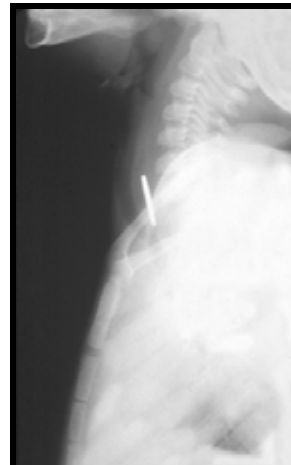
Lateral soft tissue neck views may show retained foreign bodies in the vellicula at the base of tongue, pyriform fossa or hypopharynx. In the absence of a FB they may show sequelae of trauma with soft tissue gas or a collection in the retropharyngeal region.



**BOTTLE CAP**



**COIN IN OESOPHAGUS**



**BONE**

### MASSES/CALCULI

US is the first line imaging modality in the investigation of salivary gland calculi and masses. The radiologist may then suggest further assessment with CT or MRI.

Dr Kate O'Connor

**ARG's new website is live: [www.arg.co.nz](http://www.arg.co.nz)**